



Jose Luis Tapia

## Indications and procedures for direct immunofluorescence biopsies of the oral mucosa

Jose Luis Tapia, DDS, MS<sup>1</sup>/Mirdza E. Neiders, DDS,MS<sup>2</sup>/Lakshmanan Suresh, DDS, MS<sup>3</sup>

A definitive diagnosis is crucial for management of any oral mucosal disease. Direct immunofluorescence (DIF) is a valuable diagnostic aid for immune-mediated blistering diseases and systemic connective tissue diseases of the skin and the mucosa. This paper gives an overview of the DIF biopsy technique

for oral lesions and provides a background for the clinician to optimize the utilization of DIF biopsy. The key characteristic diagnostic findings of DIF of specific mucosal diseases are also discussed. (doi: 10.3290/j.qi.a32921)

**Key words:** direct immunofluorescence, immune-mediated blistering diseases, oral vesiculobullous disease, oral biopsy technique, systemic connective tissue diseases

Direct immunofluorescence (DIF) technique is used to identify tissue-bound antibodies in autoimmune diseases by the use of fluorescein-labeled antibodies. DIF has been very useful in the diagnosis of immune-mediated blistering diseases and systemic connective tissue diseases of the skin and the mucosa.<sup>1,2</sup> DIF is helpful in supporting, confirming, differentiating, and/or ruling out diagnosis between various immune-mediated blistering diseases affecting oral mucosa. The use of DIF is helpful in confirming the diagnosis for mucous membrane pemphigoid,<sup>3</sup> pemphigus vulgaris,<sup>4</sup> linear immu-

noglobulin A (IgA) disease,<sup>5</sup> chronic ulcerative stomatitis,<sup>6</sup> dermatitis herpetiformis,<sup>7</sup> and epidermolysis bullosa acquisita.<sup>8</sup> DIF testing is also considered an important adjunct for the diagnosis in oral lichen planus,<sup>9</sup> systemic lupus erythematosus, scleroderma, and mixed connective tissue disease.<sup>2</sup> The results of DIF are correlated with clinical, serologic, and histopathologic findings to differentiate between immune-mediated blistering diseases and from other erosive and ulcerative lesions affecting the oral mucosa.

When immune-mediated blistering diseases occur in the oral cavity, the general dental practitioner is usually the individual that sees the initial phases of these diseases. Therefore, the general dental practitioner has to be aware of the signs, symptoms, and methods for diagnosis of the immune-mediated blistering diseases. This leads to an early diagnosis and the control of these diseases at their initial phases resulting in less discomfort and complications.

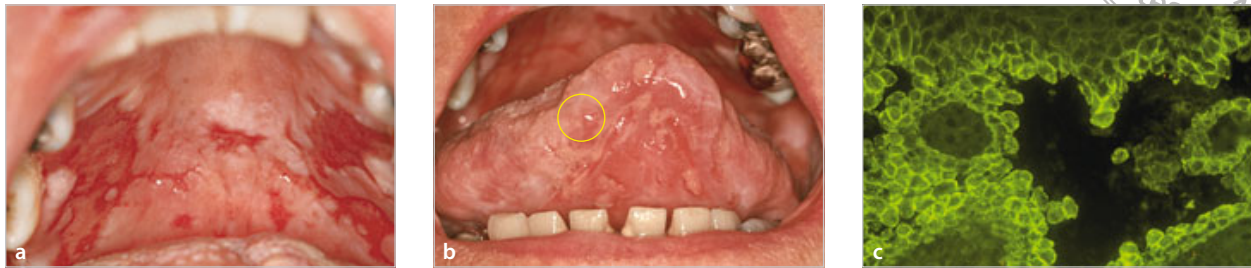
Important factors including clinical indications, biopsy site, technique, specimen collection, handling, and processing are crucial in maximizing the utilization

<sup>1</sup> Assistant Professor, Department of Oral Diagnostic Sciences, School of Dental Medicine, State University of New York at Buffalo, Buffalo, New York, USA.

<sup>2</sup> Distinguished Teaching Professor, Department of Oral Diagnostic Sciences, School of Dental Medicine, State University of New York at Buffalo, Buffalo, New York, USA; and Assistant Director of Diagnostic Immunology, IMMCO Diagnostics, Buffalo, New York, USA.

<sup>3</sup> Clinical Associate Professor, Department of Oral Diagnostic Sciences, School of Dental Medicine, State University of New York at Buffalo, Buffalo, New York, USA; and Vice President of Clinical Service, Research and Development, IMMCO Diagnostics, Buffalo, New York, USA.

**Correspondence:** Dr Jose Luis Tapia, 355 Squire Hall, Department of Oral Diagnostic Sciences, School of Dental Medicine, State University of New York at Buffalo, Buffalo, NY 14214, USA. Email: jltapia2@buffalo.edu



**Figs 1a to 1c** A 78-year-old woman with multiple ulcerations of the oral mucosa (courtesy of Dr Stanley Kerpel). (a) Extensive ulcerations of attached palatal mucosa making it difficult to select an area with intact epithelium. (b) Multiple ulcerations on the ventral surface of the tongue. Ideal site of biopsy in this patient is shown in the yellow circle. Intact epithelium should cover the biopsy specimen. DIF studies revealed that this case represents pemphigus vulgaris. (c) DIF study representative of pemphigus vulgaris. DIF profile is characterized by intercellular deposition of IgG in the epithelium (magnification 10×).

of the DIF biopsy. The purpose of this paper is to provide an overview of the above factors to the clinician for optimal use of the DIF biopsy.

### Indications for DIF biopsy

A definitive diagnosis is critical for the appropriate management of oral mucosal diseases. DIF biopsy may be an aid in establishing definitive diagnosis in the following conditions:

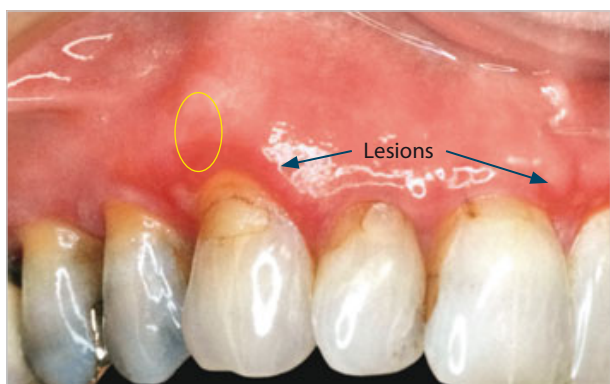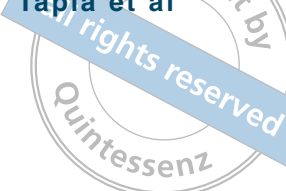- If the clinician suspects that a persistent vesiculobullous, or erosive or ulcerative oral lesions represent an immune-mediated disease, DIF studies may be required. The common denominator of immune-mediated blistering diseases and systemic connective tissue diseases is the persistence of an oral lesion for more than several weeks. Most of these diseases will show ulceration, erythema, and sloughing of epithelium with or without positive Nikolsky's sign. Also, definitive diagnosis of the underlying disease in desquamative gingivitis requires a DIF biopsy. Hematoxylin-eosin (h&e) biopsy should accompany the DIF biopsy to establish the definite biopsy for lesions that may not show immunofluorescence findings. Other diseases, including malignancy, may mimic immunologically mediated diseases.<sup>7,10</sup>
- DIF biopsy may be taken by request of the oral pathologist after examination of h&e biopsy. DIF is considered the gold standard for diagnosis of some of the immune-mediated blistering diseases and confirmation of diagnosis may be necessary for

appropriate treatment.<sup>11</sup> In addition, sometimes the h&e findings are not specific enough to separate some of the disease entities from each other.

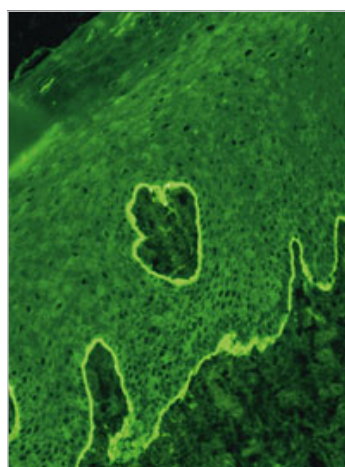
- If a nonspecific diagnosis of chronic inflammation is given to the oral pathologist based on h&e biopsy and the lesion still persists, DIF biopsies may help in establishing definitive diagnosis. The h&e biopsy may have been taken from an area that is not representative of the disease process. Immunologically mediated diseases undergo cycles of exacerbation and quiescence making selection of the biopsy site a problem.

### Biopsy site selection

Biopsy site selection for h&e studies has been outlined by Melrose et al.<sup>12</sup> The selection of an appropriate biopsy site is also critical for DIF studies.<sup>13</sup> Dermatologic literature recommends the taking of two biopsies: one from lesional/perilesional site with intact epithelium and one from adjacent normal tissue.<sup>1</sup> Areas of blister formation and ulceration should be avoided (Fig 1a).<sup>13</sup> Sano et al<sup>14</sup> has also shown that biopsies in oral cavity from multiple sites have a better diagnostic sensitivity rate than biopsies from a single site. This has also been shown in other studies.<sup>7</sup> The h&e biopsy site should be selected from a lesional site adjacent to the DIF biopsy site. Epithelial covering is required for all biopsies since the epithelial-connective junction is needed for establishing diagnosis (Fig 1b).



**Fig 2a** A 58-year-old woman with multiple erythematous lesions (blue arrows) on the gingiva. An elliptical incisional (yellow) biopsy for DIF studies was taken.



**Fig 2b** DIF studies revealed that this case represents mucous membrane pemphigoid. DIF study showed a linear band of IgG at basement membrane zone (magnification 40x).

### Biopsy technique

There are not many studies about the best method of taking biopsies for DIF from oral mucosa. Sano et al<sup>14</sup> have shown that punch biopsy samples have a greater detection rate for DIF than those taken with a scalpel. However, taking a biopsy with a punch in the oral cavity may have certain problems. These occur due to a lack of experience with punch biopsies by the practitioner, the ease with which the epithelium slides off in this biopsy procedure, and the difficulty of using the punch on unattached mucosa and all sites in the oral cavity. Siegel<sup>15</sup> suggests a wedge-shaped incisional biopsy from a perilesional site to be bisected and submitted for both h&e and DIF studies (Fig 2). This approach is acceptable if the sample is large enough to provide adequate tissue for both procedures. However, tiny samples provide difficulties for the technician in producing quality slides and may also impair the pathologist's ability to provide specific diagnosis.<sup>12</sup> As there is a problem in some immune-mediated blistering diseases with fragile epithelium, a DIF specimen from adjacent normal tissue is necessary.

The biopsy procedure for DIF is similar for all the mucosal tissues (floor of the mouth, ventral side of the tongue, soft-palate, lip, and keratinized mucosa such as palate), except for gingiva. For gingival biopsies the incisions need to be extending to the bone and must

be dissected from the underlying periosteum before submission of the tissue.<sup>16</sup>

The site of the biopsy may also determine if an incisional or punch biopsy is possible. Palatal and gingival sites do not generally allow adequate biopsies using the punch biopsy technique, making incisional biopsy the technique of choice. Traditional incisional biopsies are in the shape of an ellipse, the length of which should be approximately three times the width.<sup>17</sup> The specimen should be a minimum of 4 to 5 mm in length. The specimen should also be deep enough to include the basement membrane and the underlying connective tissue (at least 3 to 4 mm).<sup>16,18</sup> The specimens should be placed immediately in the appropriate solution (Michel's buffer for normal and lesion biopsy, formalin for h&e biopsy) and labeled with the site and the patient's name.

Orientation markers are commonly done in excisional biopsies to establish if a lesion has been adequately excised. Orientation is accomplished by placing one or several sutures and informing the pathologist as to the location of suture placements. If the specimen is thin and fragile, it is advisable to place it on a piece of thick paper, with the connective tissue side down, for at least 1 minute to ensure that the sample stays flat during fixation. Usually the punch or the incisional biopsies do not require any orientation makers.<sup>16,18</sup>



### Clinical diagnosis and dental/medical history

Recording of clinical diagnosis is a method for the clinician to communicate to the pathologist his impression of the diagnosis that he has obtained from the clinical findings and patient's history. In a considerable number of instances the definitive diagnosis depends on correlation of clinical findings and medical history along with h&e and DIF results. For example, recent publications indicate that lichen planus cannot be differentiated from lichenoid reaction on histologic examination.<sup>19</sup> The lichenoid reactions include drug reactions and allergic reactions to filling materials and other substances.<sup>20</sup> To differentiate lichenoid reactions from lichen planus, it is necessary to describe the distribution of the lesions, and obtain a history of allergens and the list of medications.<sup>21</sup> DIF findings of lichenoid lesions have not yet been sufficiently investigated to determine whether they are similar or different from lichen planus. Comprehensive history of systemic diseases, particularly autoimmune diseases and dermatologic diseases, may be also helpful in establishing diagnosis of vesiculobullous diseases. This is important because various systemic connective tissue diseases present with oral manifestations and sometimes they are the only sign of the disease.<sup>22</sup>

### Method of submission and specimen handling

The diagnosis of immunologically mediated diseases of oral mucosa requires biopsies for h&e and DIF studies.

#### H&e biopsy


For the h&e biopsy, the tissue specimens received in 10% formalin are processed using routine techniques consisting of dehydration in gradations of alcohols, cleared in xylene, and embedded in paraffin. Five-micron tissue sections are cut on a microtome and mounted on glass slides. The tissue sections are stained by h&e and examined with a light microscope by an oral pathologist. A biopsy report is issued with the histologic diagnosis.

#### DIF biopsy

DIF techniques were developed using unfixed frozen tissues cut with a cryostat. Initially, the tissue biopsies used for immunofluorescence studies were snap frozen in dry ice or liquid nitrogen and transported to the laboratory in the frozen state. Problems arose because snap freezing was not possible in all clinical areas and transportation of tissue in a frozen state can be difficult.<sup>23</sup> Therefore, many transport media and methods have been tried to maximize both quality of immunofluorescence examination and the ease of use.

A medium for transport of specimens was first described by Michel et al.<sup>23</sup> This medium contains proteolytic enzyme inhibitor (n-ethylmaleimide) and has a high salt concentration (ammonium sulfate) in a buffer with neutral pH. The medium can be stored at room temperature for 1 year without any deterioration.<sup>24</sup> Any visible precipitation or cloudiness indicates deterioration of the transport medium and it should not be used for the submission of specimens. Many transport media have been developed over time,<sup>25,26</sup> but Michel's transport medium remains the most widely used.<sup>27,28</sup>

When the biopsies for DIF are received in the laboratory they are washed in a buffer solution. Each specimen is removed from wash buffer and mounted on a block by snap freezing on dry ice. Four- to six-micron tissue sections are obtained and two to three sections are placed on each five-well adhesive coated slide. The tissues are allowed to dry at ambient temperature for 20 minutes and then washed in phosphate buffered saline containing sodium azide (PBS-A). The sections are stained for bound IgG, IgA, IgM, fibrin, and complement C3 using fluorescein-labeled goat anti-human conjugates. In some cases, depending on the clinical impression or immunofluorescence findings, staining with mouse human anti-IgG4 or anti-C5b-9 conjugate is also performed.<sup>29,30</sup> Slides with the conjugates are incubated for 30 minutes (at room temperature) in a moist incubation chamber protected from light. After incubation, slides are washed in PBS-A and placed in the PBS-A for an additional 10 minutes. Each slide is cover slipped using mounting medium.



**Table 1** The site, pattern, immunofluorescence, and presence of circulating antibody in autoimmune diseases

Dis- ease	Site	Pattern in DIF	Biopsy								Serum anti- bodies	Method of detection of serum antibodies	Refer- ences	
			N/L	IgG	IgA	IgM	Fibrin	C3	IgG4	C5b-9				
PV	IC	Inter- cellular	+	+	+	±	-	-	+	+	-	+ (Dsg-1, Dsg-3)	IIF/ELISA; primate/guinea pig esophageal epithelium & human skin	32, 33
PNP	IC	Inter- cellular	+	+	+	-	-	-	+	-	-	+ (Plakins)	IIF/ELISA; rat bladder	34, 35, 36
	BMZ	Linear	±	±	±	-	-	-	±	-	-	None	None	None
MMP	BMZ on epithe- lial and CT side	Linear	+	±	+	±	-	-	+	+	-	+ (BP 180/230)	IIF/ELISA; primate esophageal epithelium & human skin	3, 37, 38
LAD	BMZ	Linear	+	+	±	+	-	-	±	-	-	+ (LAD-1)	WB	39
DH	BMZ	Granular	-	+	±	+	-	-	±	-	-	+ (tTG, EMA)	IIF/ELISA; primate bladder, esophagus/human umbilicus	2, 40, 41
EBA	BMZ on the CT side	Linear	+	+	+	±	-	-	+	-	-	+ (Type VI collagen)	IIF/ELISA; primate bladder, distal esophagus/human umbilicus	2, 41, 42
OLP	BMZ	Shaggy	-	+	-	-	-	+	-	-	-	None	None	9
CUS	Nuclear	Speckled	-	+	+	-	-	-	-	-	-	+ (SES-ANA)	IIF; primate esophageal epithelium	6, 43
	BMZ	Shaggy	-	+	-	-	-	+	-	-	-	None	None	None
SLE/ SCLE	BMZ/CT	Granular	+	+	±	±	+	-	±	-	-	+ (ANA, vari- ous ENA's)	IIF/ELISA; HEp-2/mouse kidney	2, 31
	Nuclear	Various patterns, mainly speckled	+	+	+	-	-	-	-	-	-	None	None	None
DLE	BMZ/CT	Granular	-	+	±	-	+	-	±	-	-	+ (ANA, vari- ous ENA's)	IIF/ELISA; HEp-2/mouse kidney	2, 31
	Nuclear	Various patterns/ mainly homo- geneous	-	+	+	-	-	-	-	-	-	None	None	None
SSc	Nuclear	Centro- mere/ nuclear dots	+	+	+	-	-	-	-	-	-	+ (ANA, Scl 70, PM-Scl)	IIF/ELISA; HEp-2/mouse kidney	2, 31
MCTD	Nuclear	Speckled/ homo- geneous	+	+	+	-	-	-	-	-	+	+ (ANA, U1 RNP)	IIF/ELISA; HEp-2/mouse kidney	2, 31

ANA, antinuclear antibody; BMZ, basement membrane zone; BP, bullous pemphigoid antigens; CT, connective tissue; CUS, chronic ulcerative stomatitis; DH, dermatitis herpetiformis; DLE, discoid lupus erythematosus; Dsg, desmogleins; EBA, epidermolysis bullosa acquisita; ELISA, enzyme linked immunosorbent assay; EMA, endomysial antibody; ENA, extractable nuclear antigen; HEp-2, human epithelial cell line 2; IC, intercellular; IIF, indirect immunofluorescence; LAD, linear IgA disease; MCTD, mixed connective tissue disease; MMP, mucous membrane pemphigoid; N/L, normal/lesional; OLP, oral lichen planus; PM-Scl, polymyositis-scleroderma antibody; PNP, paraneoplastic pemphigus; PV, pemphigus vulgaris; Scl-70 (anti-topoisomerase 1), scleroderma antibody; SCLE, subacute cutaneous lupus erythematosus; SES, stratified epithelial specific antibody; SLE, systemic lupus erythematosus; SSc, systemic sclerosis; tTg, tissue transglutaminase; U1 RNP, small nuclear ribonucleoproteins; WB, Western blot.



In some cases a more precise localization of the immunoreactants (bound antibody) is needed.<sup>31</sup> Incubating the normal skin with 1 mol/L solution of sodium chloride separates the epidermis from the dermis. Localization of the immunoreactants with the epidermal or dermal side may further identify the specific disease. Thus, in mucous membrane pemphigoid the immunodeposits may be on both sides of the salt-split tissue assay, while in epidermolysis bullosa acquisita the immunodeposits show localization on the floor of the saline-induced split.

### Interpretation

Interpretation of DIF is made by a pathologist using a fluorescence microscope with the following characteristic: XCITE 120 bulb (high pressure 120 watt metal halide short arc 200× magnification employing FITC-3540B-NTE filter combination).

The report to the clinician includes the positive findings with a particular reagent and the site and pattern of the reagent deposits (Table 1). The diagnosis is given as being consistent, suggestive, or not consistent with the clinical diagnosis given by the clinician. If the pattern is consistent with some other immunopathologically identifiable diseases, the diagnosis for this disease is given. A comment is added if additional information or serum is needed to confirm this disease.

In most cases of vesiculobullous diseases the definitive diagnosis is based on a combination of clinical, histologic, immunopathologic, and sometimes serologic findings. In some of the cases the diagnosis may be very descriptive and inconclusive. There may also be instances when clinical impression may not correlate with the histologic findings. For these cases it is good practice to discuss the case with the pathologist to ascertain the significance of the histologic to the clinical findings.

Serology studies are helpful as an additional diagnostic marker in lupus, dermatitis, scleroderma, paraneoplastic pemphigus, and dermatitis herpetiformis. In cases of pemphigus, pemphigoid, and lupus erythematosus, circulating antibodies in the serum may be used for treatment monitoring purposes. DIF studies require

high specialization and training and are not available widely. However, serology studies are much more common and are commonly used for diagnostic purposes when DIF is not available.

In summary, this paper outlines the indications for the DIF biopsy and provides a background of this procedure for the dental practitioner. It is important that the clinician is aware of the use of DIF studies in the diagnosis of oral disease. An accurate diagnosis of oral lesions is part of any comprehensive dental care. DIF biopsies have been proven to be help in supporting and confirming various diseases that may affect the oral cavity.

### ACKNOWLEDGMENT

The authors thank Dr Sophia Elmuradi for her valuable contribution to the manuscript.

### REFERENCES

- Morrison LH. Direct immunofluorescence microscopy in the diagnosis of autoimmune bullous dermatoses. *Clin Dermatol* 2001;19:607–613.
- Mutasim DF, Adams BB. Immunofluorescence in dermatology. *J Am Acad Dermatol* 2001;45:803–822.
- Chan LS, Ahmed AR, Anhalt GJ, et al. The first international consensus on mucous membrane pemphigoid: definition, diagnostic criteria, pathogenic factors, medical treatment, and prognostic indicators. *Arch Dermatol* 2002;138:370–379.
- Casiglia J, Woo SB, Ahmed AR. Oral involvement in autoimmune blistering diseases. *Clin Dermatol* 2001;19:737–741.
- Zone JJ. Clinical spectrum, pathogenesis and treatment of linear IgA bullous dermatosis. *J Dermatol* 2001;28:651–653.
- Solomon LW, Aguirre A, Neiders M, et al. Chronic ulcerative stomatitis: clinical, histopathologic, and immunopathologic findings. *Oral Surg Oral Med Oral Pathol Oral Radiol Endod* 2003;96:718–726.
- Suresh L, Neiders ME. Definitive and differential diagnosis of desquamative gingivitis through direct immunofluorescence studies. *J Periodontol* 2012;83:1270–1278.
- Schifter M, Yeoh SC, Coleman H, Georgiou A. Oral mucosal diseases: the inflammatory dermatoses. *Aust Dent J* 2010;55(Suppl 1):S23–S38.
- Laskaris G, Sklavounou A, Angelopoulos A. Direct immunofluorescence in oral lichen planus. *Oral Surg Oral Med Oral Pathol* 1982;53:483–487.
- Rinaggio J, Crossland DM, Zeid MY. A determination of the range of oral conditions submitted for microscopic and direct immunofluorescence analysis. *J Periodontol* 2007;78:1904–1910.
- Position paper: oral features of mucocutaneous disorders. *J Periodontol* 2003;74:1545–1556.
- Melrose RJ, Handlers JP, Kerpel S, Summerlin DJ, Tomich CJ, American Academy of Oral Maxillofacial Pathology. The use of biopsy in dental practice. The position of the American Academy of Oral and Maxillofacial Pathology. *Gen Dent* 2007;55:457–461.

13. Black MM, Bhogal BS, Willsteed E. Immunopathological techniques in the diagnosis of bullous disorders. *Acta Derm Venereol* 1989;151(Suppl):S96–S105.
14. Sano SM, Quarracino MC, Aguas SC, et al. Sensitivity of direct immunofluorescence in oral diseases. Study of 125 cases. *Med Oral Patol Oral Cir Bucal* 2008;13:287–291.
15. Siegel MA. Intraoral biopsy technique for direct immunofluorescence studies. *Oral Surg Oral Med Oral Pathol* 1991;72:681–684.
16. Oliver RJ, Sloan P, Pemberton MN. Oral biopsies: methods and applications. *Br Dent J* 2004;196:329–333.
17. Golden DP, Hooley JR. Oral mucosal biopsy procedures. Excisional and incisional. *Dent Clin North Am* 1994;38:279–300.
18. Avon SL, Klieb HB. Oral soft-tissue biopsy: an overview. *J Can Dent Assoc* 2012;78:c75.
19. Schlosser BJ. Lichen planus and lichenoid reactions of the oral mucosa. *Dermatol Ther* 2010;23:251–267.
20. Muller S. Oral manifestations of dermatologic disease: a focus on lichenoid lesions. *Head Neck Pathol* 2011;5:36–40.
21. Wright J. Diagnosis and management of oral lichenoid reactions. *J Calif Dent Assoc* 2007;35:412–416.
22. Klasser GD, Balasubramaniam R, Epstein J. Topical review – connective tissue diseases: orofacial manifestations including pain. *J Orofac Pain* 2007;21:171–184.
23. Michel B, Milner Y, David K. Preservation of tissue-fixed immunoglobulins in skin biopsies of patients with lupus erythematosus and bullous diseases: preliminary report. *J Invest Dermatol* 1972;59:449–452.
24. Huilgol SC, Bhogal BS, Black MM. Immunofluorescence of the immunobullous disorders part one: Methodology. *Indian J Dermatol Venereol Leprol* 1995;61:187–195.
25. Jonsson R, Kristensson-Aas A, Kutti J. Assessment of a tissue transport-medium in preservation of tissue-fixed immunoglobulins and complement demonstrated by direct immunofluorescence. A pilot study with skin from SLE patients. *J Clin Pathol* 1978;31:823–826.
26. Niedecken HW, Lange CE. Simplified fixative medium for direct immunofluorescence in skin biopsies. *J Am Acad Dermatol* 1985;12:828–831.
27. Vaughn Jones SA, Palmer I, Bhogal BS, Eady RA, Black MM. The use of Michel's transport medium for immunofluorescence and immunoelectron microscopy in autoimmune bullous diseases. *J Cutan Pathol* 1995;22:365–370.
28. Fischer EG. To fix or not to fix: Michel's is the solution. *Int J Surg Pathol* 2006;14:108.
29. Suresh L, Kumar V. Significance of IgG4 in the diagnosis of mucous membrane pemphigoid. *Oral Surg Oral Med Oral Pathol Oral Radiol Endod* 2007;104:359–362.
30. Vasil KE, Magro CM. Cutaneous vascular deposition of C5b-9 and its role as a diagnostic adjunct in the setting of diabetes mellitus and porphyria cutanea tarda. *J Am Acad Dermatol* 2007;56:96–104.
31. Magro CM, Roberts-Barnes J, Crowson AN. Direct immunofluorescence testing in the diagnosis of immunobullous disease, collagen vascular disease, and vascular injury syndromes. *Dermatol Clin* 2012;30:763–798.
32. Beutner EH, Jordon RE. Demonstration of skin antibodies in sera of pemphigus vulgaris patients by indirect immunofluorescent staining. *Proc Soc Exp Biol Med* 1964;117:505–510.
33. Ishii K, Amagai M, Hall RP, et al. Characterization of autoantibodies in pemphigus using antigen-specific enzymelinked immunosorbent assays with baculovirus-expressed recombinant desmogleins. *J Immunol* 1997;159:2010–2017.
34. Anhalt GJ. Paraneoplastic pemphigus. *J Investig Dermatol Symp Proc* 2004;9:29–33.
35. Zimmermann J, Bahmer F, Rose C, Zillikens D, Schmidt E. Clinical and immunopathological spectrum of paraneoplastic pemphigus. *J Dtsch Dermatol Ges* 2010;8:598–605.
36. Probst C, Schlumberger W, Stöcker W, et al. Development of ELISA for the specific determination of autoantibodies against envoplakin and periplakin in paraneoplastic pemphigus. *Clin Chim Acta* 2009;410:13–18.
37. Jordon RE, Beutner EH, Witebsky E, Blumental G, Hale WL, Lever WF. Basement zone antibodies in bullous pemphigoid. *J Am Med Assoc* 1967;200:751–756.
38. Sitaru C, Dahnrich C, Probst C, et al. Enzymelinked immunosorbent assay using multimers of the 16th non-collagenous domain of the BP180 antigen for sensitive and specific detection of pemphigoid autoantibodies. *Exp Dermatol* 2007;16:770–777.
39. Marinkovich MP, Taylor TB, Keene DR, Burgeson RE, Zone JJ. LAD-1, the linear IgA bullous dermatosis autoantigen, is a novel 120-kDa anchoring filament protein synthesized by epidermal cells. *J Invest Dermatol* 1996;106:734–738.
40. Dieterich W, Ehnis T, Bauer M, et al. Identification of tissue transglutaminase as the autoantigen of celiac disease. *Nat Med* 1997;3:797–801.
41. Eming R, Hertl M. Autoimmune bullous diseases. *Clin Chem Lab Med* 2006;44:144–149.
42. Chen M, Chan LS, Cai X, O'Toole EA, Sample JC, Woodley DT. Development of an ELISA for rapid detection of anti-type VII collagen autoantibodies in epidermolysis bullosa acquisita. *J Invest Dermatol* 1997;108:68–72.
43. Beutner EH, Chorzelski TP, Parodi A, et al. Ten cases of chronic ulcerative stomatitis with stratified epithelium-specific antinuclear antibody. *J Am Acad Dermatol* 1991;24:781–782.